



**MAX**  
Healthcare

Age: 54 Years	Sex: Male
UHID No: 070987975	Bed No: 2452
Date of Admission: 17.06.2023	Date of Discharge: 22.06.2023
Consultant: Dr. Rayaz Khalid Ahmed	Location: Max 4th floor Saket

Max Id: SKDD.987975      IP No: 491076  
Name: Mr. SHAKEEL AHMAD  
Bed No: 2452E      Age/Sex: 54 Years 8 Months/Male  
Consultant: Rayaz Ahmed Md DOA: 17/6/2023 7:09:02PM  
Phone Number: 9643651107  
*RA*



**MAX CANCER CENTER**  
**DEPARTMENT OF HEMATOLOGY ONCOLOGY**  
**DISCHARGE SUMMARY**

Patient's Name: Mr. Shakeel Ahmad	
Age: 54 Years	Sex: Male
UHID No: 070987975	Bed No: 2452
Date of Admission: 17.06.2023	Date of Discharge: 22.06.2023
Consultant: Dr. Rayaz Khalid Ahmed	Location: Max 4th floor Saket
Diagnosis: Multiple Myeloma with fracture of D10 vertebra	
Treatment given: Bring all outside reports including Bone marrow biopsy, FISH reports Supportive care + 1 <sup>st</sup> week chemotherapy with VCD regimen	
Next follow up: 1 <sup>st</sup> dose of Zoldria 4mg + 2 <sup>nd</sup> week chemotherapy with VCD regimen is due on 27.06.2023 with CBC, KFT, LFT with uric acid and calcium reports	
Plan: weekly VCD regimen → reassessment Monthly Inj Zoldria 4mg	

**BRIEF SUMMARY:** Mr. Shakeel Ahmad, 54 years old normotensive, diabetic male, presented with complaints of backache-lumbar -on and off since 1 years, acute severe backache since beginning of May 2023, shooting pain on axial movements, constipation, tremors in both hands(rt>>left), >10 kgs weight loss in 2 months. He was diagnosed as Diagnosed Case of Multiple Myeloma with Fracture D10 Vertebrae and AKI

Admitted for further evaluation

**INVESTIGATIONS:**

**Bone marrow (10.05.2023):** 44% plasma cells along with myeloid and erythroid series of cells. Plasma cell myeloma.

**X - ray both knee (29.05.2023):** No significant abnormality.

**X-ray both hands (29.05.2023):** Diffuse osteopenia.

**X-ray lumbar spine (29.05.2023):** Diffuse osteopenia. Degenerative spine changes.

**MRI whole spine screening with MRI LS spine (01.06.2023):** Prominent uncovertebral joints are noted. Disc desiccation noted at multiple levels. Diffuse disc bulge causing thecal sac compression and bilateral neural foraminal compression seen at C5-C6 and C6-C7 levels. Partial collapse with T2/STIR hyperintensity is noted involving the D12 vertebral body with mild retropulsion of bony fragments with no obvious cord compression, mild paravertebral edema is noted with a small collection in bilateral paravertebral region. Disc desiccation is noted at multiple levels. There is facet joint arthropathy and ligamentum flavum thickening is noted at multiple levels. Marginal anterior and posterior osteophytes are seen. Diffuse disc bulge is noted causing thecal sac compression and bilateral neural foraminal

Max Super Speciality Hospital, Saket

(East Block) - A Unit of Devki Devi Foundation

(Devki Devi Foundation registered under the Societies Registration Act XXI of 1860)

Regd. Office: 2, Press Enclave Road, Saket, New Delhi-110 017

For medical service queries or appointments, call: +91-11 2651 5050

Fax: +91-11-2651 0050

www.maxhealthcare.in





**DISCHARGE MEDICATIONS:-**

- ❖ Syp Potklor 10ml four times a day as advised x 5 days
- ❖ Mupirocin ointment to continue
- ❖ Tab Emeset 8mg thrice a day x 2 days and then if needed for vomiting -
- ❖ Tab. Febuxostat 40 mg 1 tab once daily x 1 week -
- ❖ Tab. Pantocid 40 mg 1 tab once daily before breakfast x 1 week -
- ❖ Tab. Valaciclovir 500 mg 1 tab at bedtime to continue -
- ❖ Tab. Bactrim DS 1 tab once daily at bedtime (Mon/Wed/Fri) -
- ❖ Tab. Shelcal 500 mg 1 tab twice daily continue -
- ❖ Tab crocin 650mg thrice a day to continue for pain -
- ❖ Cap Tramadol 50mg thrice a day in case of severe pain -
- ❖ Hexidine mouth wash four a day
- ❖ Tab Tayo 60k 1 tab weekly x 8 weeks
- ❖ Plenty of oral fluids

**Following medications to be taken as and when required after consultation with your respective consultant:-**

**For Vomiting: Kindly mark the ones to be prescribed**

- 1. Tab. Emeset 04/08/16/32 mg PO TDS
- 2. Tab. Domstal 10/20 mg PO TDS
- 3. Tab Aprecap 80 mg PO Daily X 2 days.
- 4. Tab. Grainsetron 1 mg PO TWICE DAILY
- 5. Tab. Dexona 02/04/08 mg twice daily x 3 days

**For Indigestion: Kindly mark the ones to be prescribed**

- 1. Tab. Pantocid 40mg PO daily 30mins before meals
- 2. Syp. Digene 2tsf PO every 6hourly
- 3. Tab. Rantac 150/300mg PO twice daily
- 4. Tab. Razo 20mg twice daily

**For Fever: Kindly mark the ones to be prescribed**

- 1. Tab. Calpol/ crocin 500 mg stat and do a CBC (Complete Blood Count)
- 2. Tab. Ciprofloxacin 500mg BD X 5 days
- 3. Cap. Augmentin Duo 625mg BDX5 days
- 4. Tab. Cefixime (200mg) BDX 5 days
- 5. Tab. Acyclovir (200 mg) ODX days
- 6. Tab. Bactrim DS

**In case of loose motions: Kindly mark the ones to be prescribed**

- 1. Cap. Imodium / Tab. Lomotil one stat and then one every 5 hrs.
- 2. Tab Redotil 100mg Po TDS
- 3. Plenty of oral fluids
- 4. O.R.S. / Electral powder (1 sachet dissolved in 1 Litre )

**In case of Constipation: Kindly mark the ones to be prescribed**

- 1. Syp. Cremaffin plus 2 tsf PO at night
- 2. Syp. Duphalac 2 tsf PO at night
- 3. Tab. Dulcolax 2 tab Po at night

**For Pain: Kindly mark the ones to be prescribed**

Super Speciality Hospital, Saket

Block) - A Unit of Devki Devi Foundation

Devi Foundation registered under the Societies Registration Act XXI of 1860)

Office: 2, Press Enclave Road, Saket, New Delhi-110 017

Medical service queries or appointments, call: +91-11 2651 5050

31-11-2651 0050

maxhealthcare.in





Provisional Transthoracic Echo-Doppler Report

Max Id: SKDD.987975	IP No: 491075	UHID :
Name: Mr. SHAKEEL AHMAD		Lab No. :
Bed No: 2452E	Age/Sex: 54 Years 8 Months/Male	Date : 18/06/23
Consultant: Rayaz Ahmed Md DOA: 17/6/2023 7:09:02PM		
Phone Number: 9643651107		

Study done at HR of bpm

1. Regional wall motion abnormality. Absent / Present <sup>85</sup>

Global LVEF  $\approx$  <sup>55-60</sup> % <sup>No RWMA</sup>

2. Chamber dimensions Normal / Abnormal

3. Gradediastolic ~~function~~ / dysfunction.  $E/e' = 11$

LVEDP Normal / Raised.

4. MR Trace, AR -, TR Trace (RVSP = mmHg)

5. TAPSE 1.9 cm, RV systolic function Normal / Abnormal.

6. IVC is Normal / Dilated, Collapsing  $>50\%$  /  $<50\%$  RA pressure 3 mmHg

7.  No Intracardiac clot/vegetation/pericardial pathology seen.

8. Normal aortic arch

Doctor's Signature *(Dr. Prabhakar)*

Doctor's Name: Dr. Prabhakar

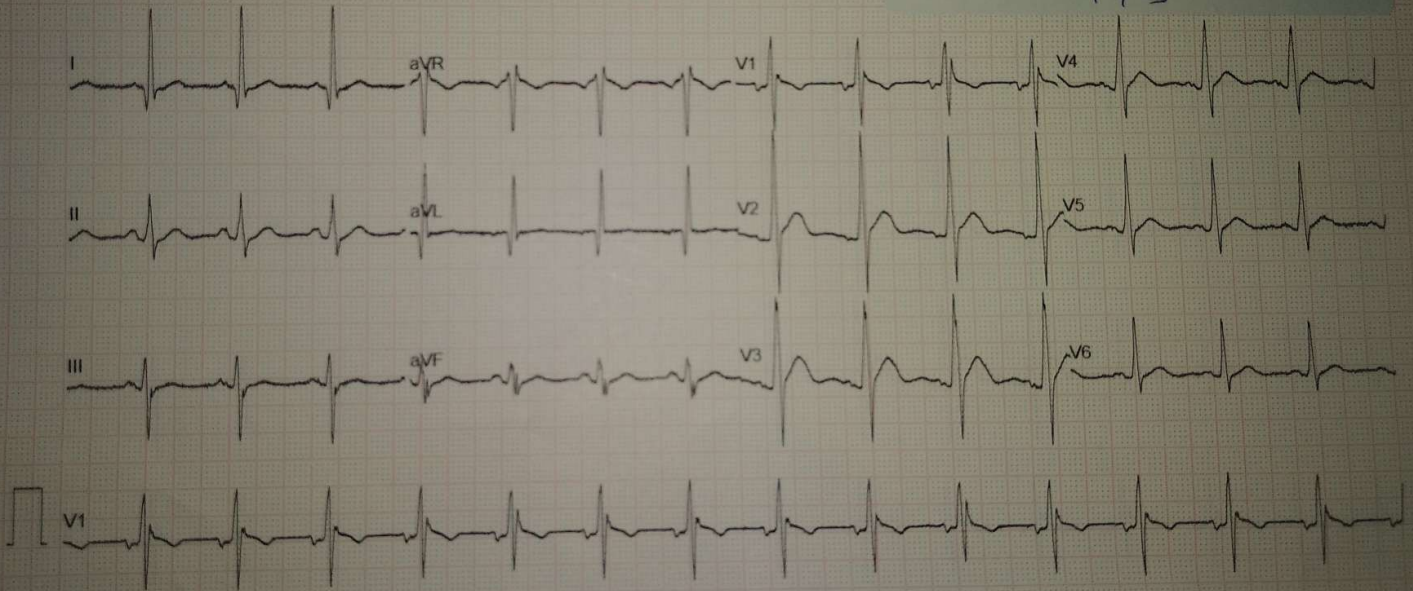
QRS : 104 ms  
QT / QTcBaz : 352 / 428 ms  
PR : 134 ms  
P : 110 ms  
RR / PP : 674 / 674 ms  
P / QRS / T : 62 / 1 / 53 degrees

Normal sinus rhythm  
Minimal voltage criteria for LVH, may be normal variant  
Nonspecific T wave abnormality  
Abnormal ECG

Technician:  
Ordering Ph:  
Referring Ph:  
Attending Ph:

Max Id: SKDD.987975 IP No: 491076  
Name: Mr. SHAKEEL AHMAD  
Bed No: 2452E Age/Sex: 54 Years 8 Months/Male  
Consultant: Rayaz Ahmed Md DOA: 17/6/2023 7:09:02PM  
Phone Number: 9643651107

17/6/23



GE MAC2000 1.1

12SL™ v241

25 mm/s 10 mm/mV

ADS 0.56-150 Hz 50 Hz

Unconfirmed  
4x2.5x3\_25\_R1



- 1. Cap. Prooxyvon 1 cap SOS
- 2. Tab. Crocin 500mg PO Three times a day
- 3. Tab. Tramadol 50 mg PO BD

**For Oral Ulcers: Kindly mark the ones to be prescribed**

- 1. Tab. Forcan 100mg PO BD For 5 days
- 2. Chlorhexidine/ Betadine gargles twice daily
- 3. Dologel for local application three times a day
- 4. Mucaine Gel 2 tsf three times a day
- 5. Boroglycerine with Tab Dexona 4 mg crushed and mixed together to be applied In mouth Three times a day.

**When and how to obtain urgent care:**

**In case of fever, excessive diarrhoea, excessive vomiting.**

**In case of emergency contact:**

Report back to your Doctor at the earliest in case of any problem/ medical emergency.


Avoid changing/ stopping medicines without medical guidance

Max Call Centre at 011- 26515050 (Saket) and 011- 43033333 (Patparganj) who will connect you to Consultant on call.

Call your consultant on the number mentioned below.

**For next cycle of admission related query - please contact - Mr. Vinod Pal, Mr. Babu (7827265066), Mr. Vishnu NP (8587811303) from 8:00am to 8:00pm.**

**In case you require sample collection, Medicine Delivery at Home or Home nursing care & Physiotherapy services please contact :- 011 - 47326969, + 91 9999777754**

  
**Dr. Rayaz Khalid Ahmed**  
 MBBS, MD, DM (Clinical Hematology)  
 Director, Haematology And Bone Marrow Transplant  
 Max Super-Specialty hospital, Saket

**Dr. Mohd Rizwan Shaikh**  
 MBBS, MD (Internal medicine)  
 DrNB (Doctorate of National board in clinical Hematology)  
 Associate Consultant  
 Max Super- Haematology And Bone Marrow Transplant

**Super Speciality Hospital, Saket**

**(Block) - A Unit of Devki Devi Foundation**

ki Devi Foundation registered under the Societies Registration Act XXI of 1860)

I. Office: 2, Press Enclave Road, Saket, New Delhi-110 017

Medical service queries or appointments, call: +91-11 2651 5050

+91-11-2651 0050

maxhealthcare.in



**MAX CANCER CENTER**  
**DEPARTMENT OF HEMATOLOGY ONCOLOGY**  
**DISCHARGE SUMMARY**

Patient's Name: Mr. Shakeel Ahmad	
Age: 54 Years	Sex: Male
UHID No: 070987975	Bed No: 2497
Date of Admission: 27.06.2023	Date of Discharge: 27.06.2023
Consultant: Dr. Rayaz Khalid Ahmed	Location: Max 4th floor Saket
Diagnosis: Multiple Myeloma with fracture of D10 vertebra	
Treatment given: 2 <sup>ND</sup> weekly VCD + 1 <sup>ST</sup> dose Inj Zoldria 4 mg	
Next follow up: 3 <sup>rd</sup> weekly chemotherapy with VCD regimen is due on 04.07.2023 with CBC, LFT, KFT with Uric Acid and Calcium reports	
Plan: weekly VCD regimen → reassessment	
Monthly Inj Zoldria 4mg	

**BRIEF SUMMARY:** Mr. Shakeel Ahmad, 54 years old normotensive, diabetic male, presented with complaints of backache-lumbar -on and off since 1 years, acute severe backache since beginning of May 2023, shooting pain on axial movements, constipation, tremors in both hands(rt>>left), >10 kgs weight loss in 2 months. He was diagnosed as Diagnosed Case of Multiple Myeloma with Fracture D10 Vertebrae and AKI.

Now admitted for 2<sup>ND</sup> weekly VCD + 1<sup>ST</sup> dose Inj Zoldria 4 mg.



**MAX CANCER CENTER**  
**DEPARTMENT OF HEMATOLOGY ONCOLOGY**  
**DISCHARGE SUMMARY**

Patient's Name: Mr. Shakeel Ahmad	
Age: 54 Years	
UHID No: 070987975	Sex: Male
Date of Admission: 27.06.2023	Bed No: 2497
Consultant: Dr. Rayaz Khalid Ahmed	Date of Discharge: 27.06.2023
Diagnosis: Multiple Myeloma with fracture of D10 vertebra	Location: Max 4th floor Saket
Treatment given: 2 <sup>ND</sup> weekly VCD + 1 <sup>ST</sup> dose Inj Zoldria 4 mg	
Next follow up: 3 <sup>rd</sup> weekly chemotherapy with VCD regimen is due on 04.07.2023 with CBC, LFT, KFT with Uric Acid and Calcium reports	
Plan: weekly VCD regimen → reassessment	
Monthly Inj Zoldria 4mg	

**BRIEF SUMMARY:** Mr. Shakeel Ahmad, 54 years old normotensive, diabetic male, presented with complaints of backache-lumbar -on and off since 1 years, acute severe backache since beginning of May 2023, shooting pain on axial movements, constipation, tremors in both hands (rt>>left), >10 kgs weight loss in 2 months. He was diagnosed as Diagnosed Case of Multiple Myeloma with Fracture D10 Vertebrae and AKI.

Now admitted for 2<sup>ND</sup> weekly VCD + 1<sup>ST</sup> dose Inj Zoldria 4 mg.

**INVESTIGATIONS:**

**Bone marrow (10.05.2023):** 44% plasma cells along with myeloid and erythroid series of cells. Plasma cell myeloma.

**X-ray both knee (29.05.2023):** No significant abnormality.

**X-ray both hands (29.05.2023):** Diffuse osteopenia.

**X-ray lumbar spine (29.05.2023):** Diffuse osteopenia. Degenerative spine changes.

**MRI whole spine screening with MRI LS spine (01.06.2023):** Prominent uncovertebral joints are noted. Disc desiccation noted at multiple levels. Diffuse disc bulge causing thecal sac compression and bilateral neural foraminal compression seen at C5-C6 and C6-C7 levels. Partial collapse with T2/STIR hyperintensity is noted involving the D12 vertebral body with mild retropulsion of bony fragments with no obvious cord compression, mild paravertebral edema is noted with a small collection in bilateral paravertebral region. Disc desiccation is noted at multiple levels. There is facet joint arthropathy and ligamentum flavum thickening is noted at multiple levels. Marginal anterior and posterior osteophytes are seen. Diffuse disc bulge is noted causing thecal sac compression and bilateral neural foraminal compression is noted at L5-S1 level. There is ligamentum flavum and facet joint hypertrophy is seen at

Max Super Speciality Hospital, Saket

(East Block) - A Unit of Devki Devi Foundation

(Devki Devi Foundation registered under the Societies Registration Act XXI of 1860)

Regd. Office: 2, Press Enclave Road, Saket, New Delhi-110 017

For medical service queries or appointments, call: +91-11 2651 5050

Fax: +91-11-2651 0050

www.maxhealthcare.in

